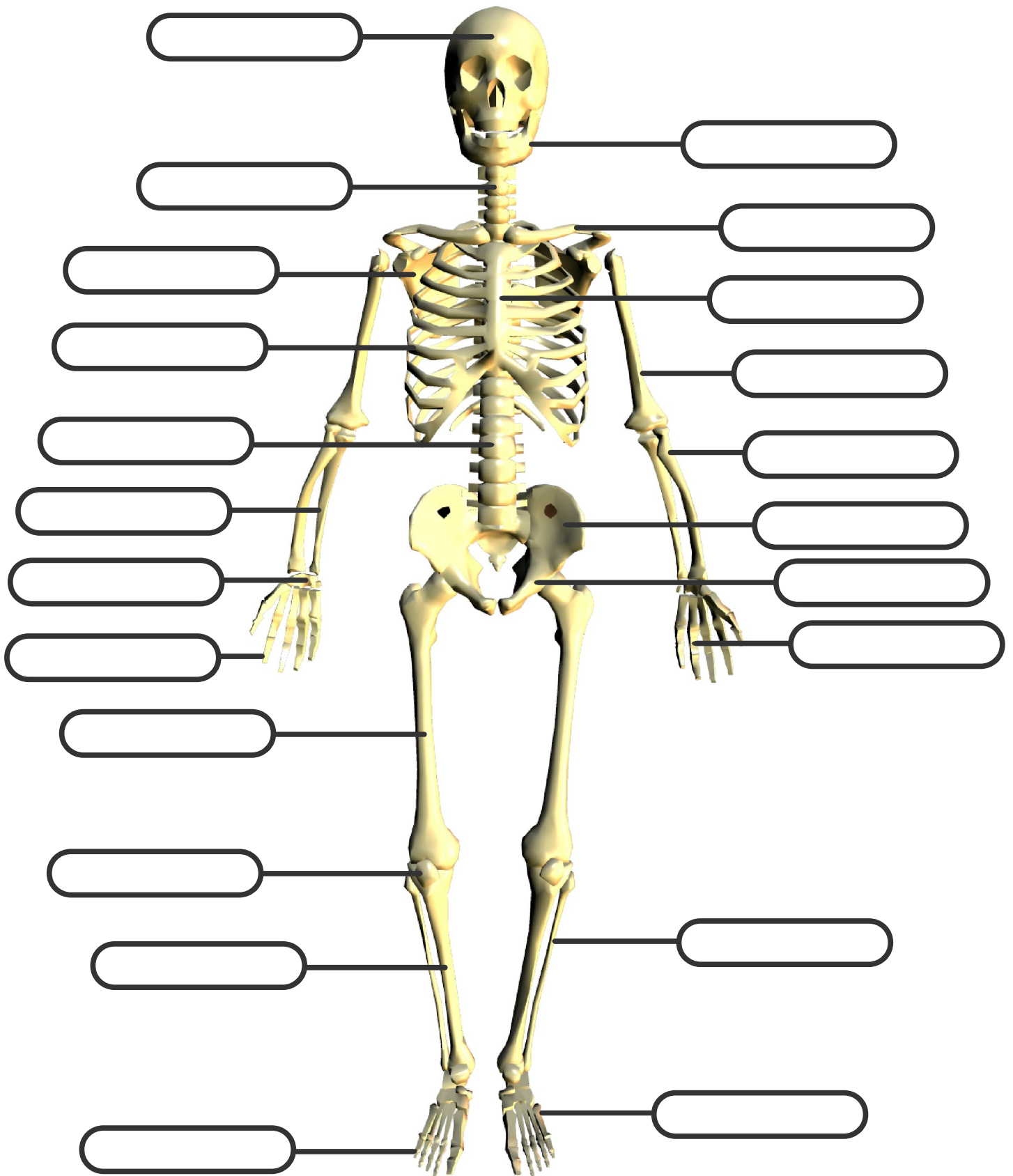


# Label the skeleton



cranium mandible cervical vertebra lumbar vertebra phalanx carpel metatarsal  
metacarpel ilium ulna rib femur tibia radius fibula sternum clavicle scapula patella  
pubis humerus