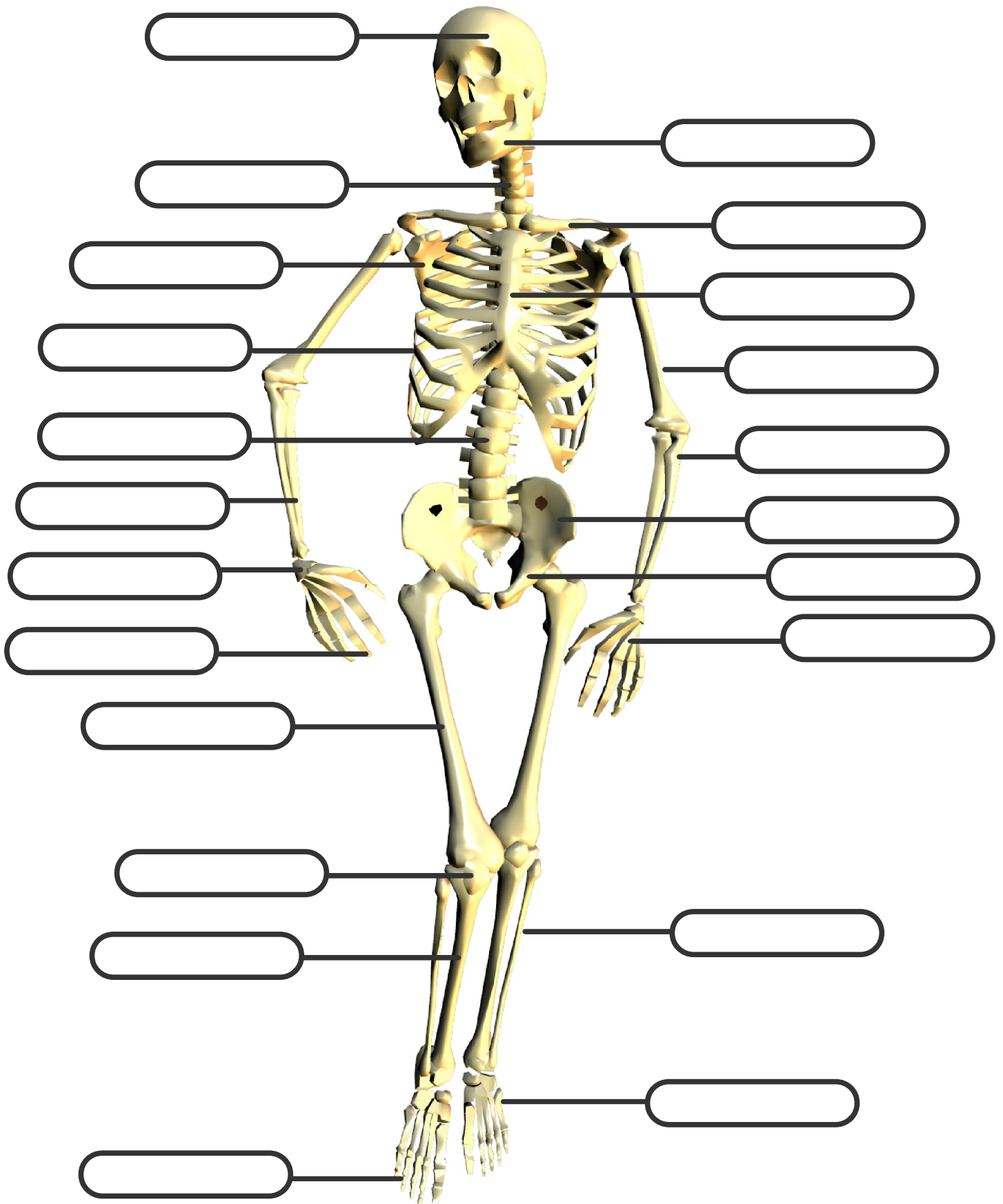


Label the skeleton



cranium mandible cervical vertebra lumbar vertebra phalanx carpel metatarsal
metacarpel ilium ulna rib femur tibia radius fibula sternum clavicle scapula patella
pubis humerus